




Hand Posture as Localizing Sign in Adult Focal Epileptic Seizures

Isabella Ferando, MD, PhD ¹, Jason R. Soss, MD,¹ Christopher Elder, MD,^{1,2}
Vishal Shah, MD,^{1,2}
Giorgio Lo Russo, MD,³ Laura Tassi, MD,³ Carlo Alberto Tassinari, MD,^{4,5} and
Jerome Engel Jr MD, PhD^{1,2,6,7,8}

Objective: The aim of this study was to identify specific ictal hand postures (HPs) as localizing signs of the epileptogenic zone (EZ) in patients with frontal or temporal lobe epilepsy.

Methods: In this study, we retrospectively analyzed ictal semiology of 489 temporal lobe or frontal lobe seizures recorded over a 6-year period at the Seizure Disorder Center at University of California, Los Angeles in the USA (45 patients) or at the C. Munari Epilepsy Surgery Center at Niguarda Hospital in Milan, Italy (34 patients). Our criterion for EZ localization was at least 2 years of seizure freedom after surgery. We analyzed presence and latency of ictal HP. We then examined whether specific initial HPs are predictive for EZ localization.

Results: We found that ictal HPs were present in 72.5% of patients with frontal and 54.5% of patients with temporal lobe seizures. We divided HPs into 6 classes depending on the reciprocal position of the fingers ("fist," "cup," "politician's fist," "pincer," "extended hand," "pointing"). We found a striking correlation between EZ localization and ictal HP. In particular, fist and pointing HPs are strongly predictive of frontal lobe EZ; cup, politician's fist, and pincer are strongly predictive of temporal lobe EZ.

Interpretation: Our study offers simple ictal signs that appear to clarify differential diagnosis of temporal versus frontal lobe EZ localization. These results are meant to be used as a novel complementary tool during presurgical evaluation for epilepsy. At the same time, they give us important insight into the neurophysiology of hand movements.

ANN NEUROL 2019;86:793–800

Epilepsy characterized by focal seizures is notoriously refractory to medical treatment (30–40% of patients).^{1,2} Half of these patients, however, will be good surgery candidates.^{1,3,4} Surgery success rates vary between 50% and 90%, depending on the epileptogenic zone (EZ) localization,⁵ the presurgical evaluation, and the procedure. Because of the high prevalence and substantial social and economic cost of medically resistant epilepsy, the development of tools that increase surgical success is of utmost importance. For purposes of planning surgery, despite the advent of more sophisticated techniques, the study of ictal and postictal

semiology remains a fundamental component of the EZ localization process. Frontal and temporal lobes are the most common localizations of focal epilepsies, and it is on these lobes that most literature focuses.⁶

Ictal behaviors are in part determined by the activation of brain areas distant from the EZ, but the EZ of the same lobe may project to similar symptomatogenic areas, giving rise to clusters of signs that are useful in the EZ localization process.⁷ Release of mesencephalic and spinal central pattern generators can also contribute to expression of behaviorally distinctive motor sequences.⁸ Literature on

View this article online at wileyonlinelibrary.com. DOI: 10.1002/ana.25589

Received Dec 27, 2018, and in revised form Aug 7, 2019. Accepted for publication Aug 25, 2019.

Address correspondence to Dr Ferando, Department of Neurology, NRB1 Room 541, David Geffen School of Medicine at UCLA, 635 Charles Young Drive South, Los Angeles, CA 90095. E-mail: iferando@ucla.edu

From the ¹Department of Neurology, David Geffen School of Medicine at University of California, Los Angeles, Los Angeles, CA; ²Seizure Disorder Center at University of California, Los Angeles, Los Angeles, CA; ³C. Munari Epilepsy Surgery Centre, Niguarda Hospital, Milan, Italy; ⁴Department of Neurology, Bellaria Hospital, Bologna, Italy; ⁵School of Medicine and Surgery, University of Bologna, Bologna, Italy; ⁶Departments of Neurobiology; ⁷Psychiatry and Biobehavioral Sciences, David Geffen School of Medicine at University of California, Los Angeles, Los Angeles, CA; and ⁸Brain Research Institute, University of California, Los Angeles, Los Angeles, CA

behavioral sequences that are suggestive of specific lateralization and localization is extensive, whereas literature on individual localizing signs is scarce.^{7–16}

To date, only a handful of signs have been proposed to have a high localizing positive predictive value (PPV). For temporal EZ localization, these include postictal nosewiping,^{12,13} ictal spitting,¹⁷ ictal whistling,¹⁸ and piloerection.^{19,20} For frontal EZ localization, they include bipedal automatisms,²¹ ictal grasping,²² and ictal pouting.²³ Unfortunately, some of these signs are so rare that they become of little clinical value on a day-to-day basis. Moreover, signs such as piloerection are not visible on video; therefore, reporting its presence is first-responder sensitive. The goal of our study was the identification of a frequent, easily recognizable localizing ictal sign as an adjunctive clinical tool to better orient presurgical evaluation. Dystonic hand and limb posturing has previously been identified as a reliable lateralizing sign in temporal lobe epilepsy,⁸ and more recently in the differential diagnosis between epileptic and nonepileptic seizures.^{24–26}

Here, we report a significant relationship between EZ localization and initial ictal hand postures (HPs). We identified a series of HPs with high sensitivity, specificity, PPV, and negative predictive value (NPV) for temporal or frontal lobe localization, with the goal of providing a novel localizing tool for presurgical evaluation in adult focal epileptic seizures.

Patients and Methods

The protocol for this study received approval by the University of California, Los Angeles (UCLA) Institutional Review Board, and written informed consent was obtained from all subjects for use of clinical data for research purposes. Written informed consent for the use of clinical data for scientific purposes was obtained from subjects admitted to the Niguarda Hospital epilepsy monitoring unit, as per Italian Law Article 13 of Legislative Decree 196/2003. A retrospective cohort of patients with drug-resistant focal epilepsy was selected from all consecutive surgeries at the Seizure Disorder Center at UCLA and the C. Munari Epilepsy Surgery Center at Niguarda Hospital in Milan over a 6-year period. All patients who met the following inclusion criteria were included in this study: (1) surgery for temporal lobe or frontal lobe epilepsy and (2) complete seizure freedom after surgery with at least 2 years of follow-up (Engel class Ia or Ib). Approximately one-third of the total surgical population at these 2 institutions, during this period, met inclusion criteria.

Long-term video-electroencephalographic (EEG) files were recorded as part of the presurgical evaluation for medically refractory epilepsy, to identify and localize the EZ. As our aim was to investigate the presence of distinct

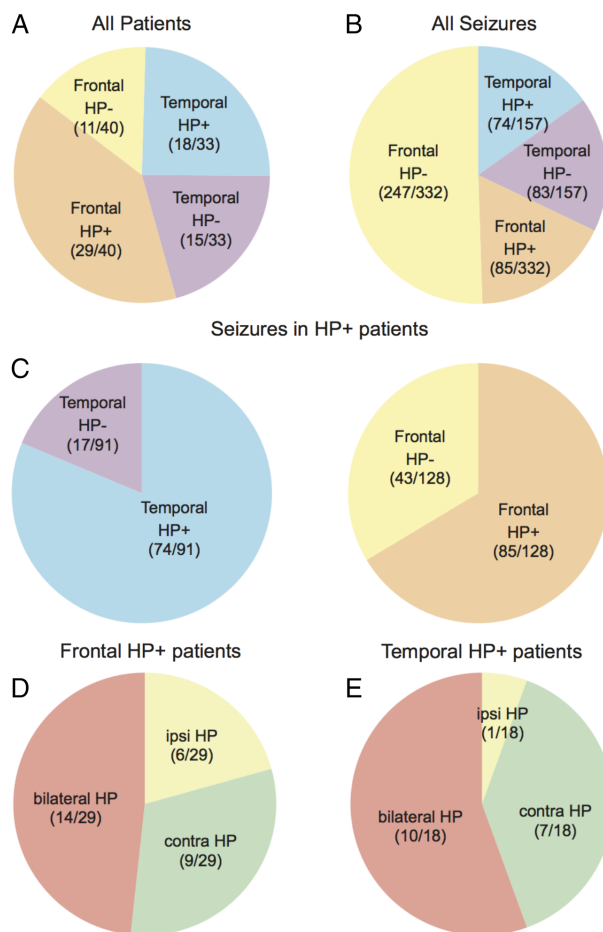


FIGURE 1: (A) Distribution of patients by localization of the epileptogenic zone (EZ localization) and presence of a hand posture (HP) in at least one seizure (HP+). Patients labeled as HP- did not show HPs in any seizure. Prevalence of ictal HP was not different between frontal and temporal lobe epilepsy (see Results). (B) Distribution of HP+ and HP- seizures by EZ localization. The majority of frontal lobe seizures were HP-, whereas half of temporal lobe seizures were HP+. This suggests that any given HP+ seizure is more likely to have an EZ localization in the temporal lobe rather than the frontal lobe. (C) HP+ patients presented with both HP+ and HP- seizures. Pie charts depict distribution of each type of seizure (HP+ or HP-) by EZ localization in HP+ patients. A greater percentage of seizures were HP+ for temporal than for frontal EZ localization (see Results). Therefore, in HP+ patients it is more likely to witness an HP+ seizure in temporal lobe rather than in frontal lobe epilepsy. (D, E) Most HP+ patients presented contralateral or bilateral HPs. Most HP+ patients presented with ipsilateral (ipsi) HPs, and they were excluded from further characterization. Contralateral (contra) HPs had shorter latency than ipsilateral HPs, measured from the beginning of the electrographic seizure. Frontal lobe seizures had shorter HP latency compared to temporal lobe seizures (see Results). [Color figure can be viewed at www.annalsofneurology.org]

HPs correlating with specific EZ localizations (temporal or frontal), long-term postresective seizure freedom allowed us to select a cohort of patients of known EZ localization.

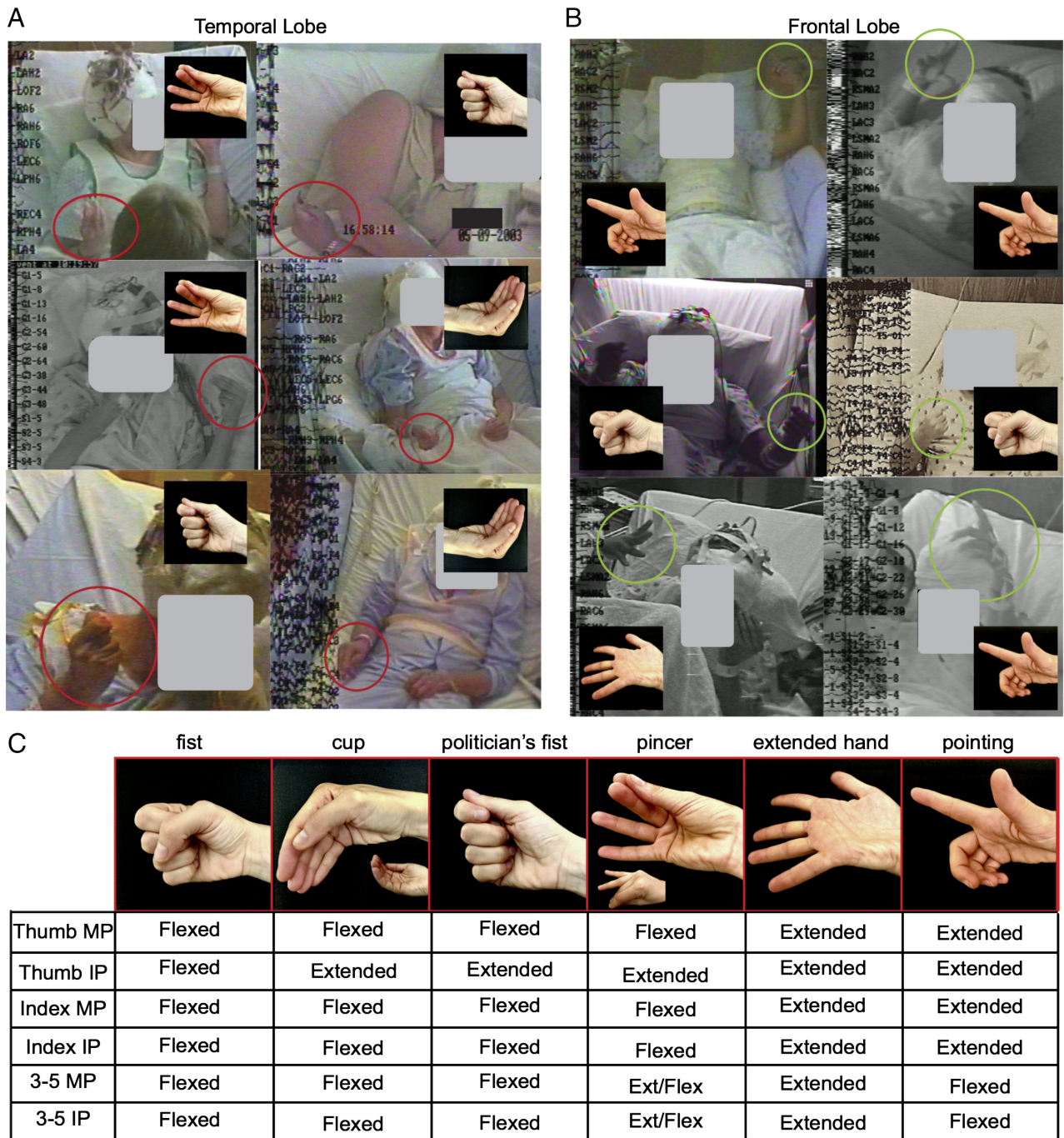


FIGURE 2: (A, B) Representative images of each ictal hand posture (HP) encountered in seizures of temporal and frontal lobe epileptogenic zone localization. Insets show reproduction of HPs for classification purposes. (C) Classification of HPs based on reciprocal positioning of fingers. Labeling of HPs was done based on hand gestures that different HPs evoke. IP = interphalangeal joint; MP = metacarpophalangeal joint. [Color figure can be viewed at www.annalsofneurology.org]

For the purposes of this study, we later labeled included patients as “temporal lobe” (33 patients) or “frontal lobe” (46 patients), depending on the localization of the resected EZ.

We defined initial ictal HP as a tonic contraction of the hand and forearm muscles lasting >5 seconds and happening as the first motor sign during focal onset impaired

awareness seizures (formerly complex partial seizures), which resulted in distinct positions of the fingers. We decided to use a threshold of 5 seconds for 2 reasons. First, for practical reasons, we wanted to study an ictal phenomenon with a duration that would not go easily unnoticed. Second, dystonic postures of the limbs previously described by Kotagal et al⁹ lasted an average of 28 seconds, with a

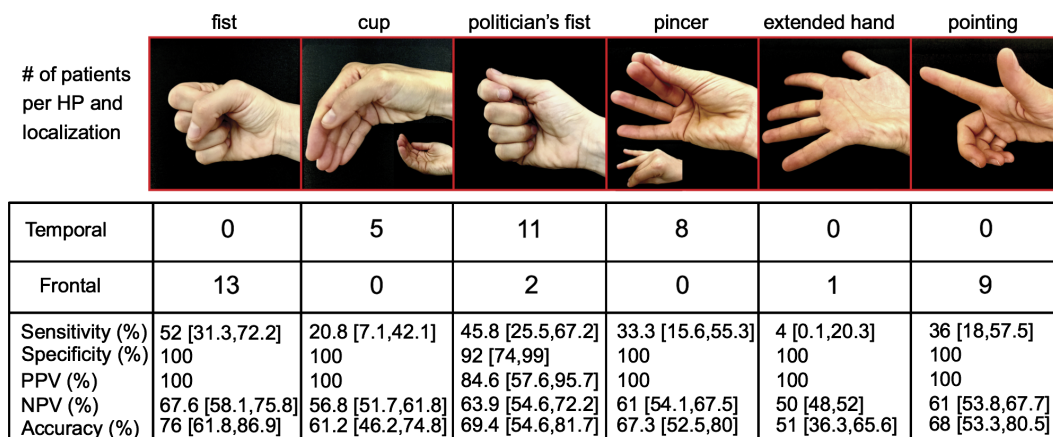


FIGURE 3: Summary of patients with different hand postures (HPs) grouped by epileptogenic zone (EZ) localization. Exact contingency table analysis reveals a significant relationship between HPs and EZ localization ($p < 0.00001$). Sensitivity, specificity, positive predictive value (PPV), negative predictive value, and accuracy are reported for each HP and EZ localization (see Results). The 95% confidence interval is reported in brackets. [Color figure can be viewed at www.annalsofneurology.org]

range between 10 and 65 seconds. With a threshold shorter than the shortest dystonic posture they observed, we wanted to include in our investigation HPs that do not necessarily fall under the definition of previously described dystonic postures (see Discussion). As our study focused on HPs alone, we did not consider the position of the hand relative to the forearm. Additionally, we disregarded all postures that arose during hand–object interactions (randomly or as part of the ictal semiology, eg, “grasping”²²), all hand positioning arising from targeted or repetitive movements (eg, “pill rolling,” “face wiping”²⁷), and all postures arising during evolution from focal to bilateral tonic–clonic seizures (formerly secondarily generalized seizures). Patients’ seizure distributions by EZ localization and presence of an HP in at least 1 seizure (HP+ patient) are presented in Figure 1.

Video-EEG was recorded and replayed using dedicated software (Stellate Harmonie Viewer; Natus Medical Incorporated, Pleasanton, CA). One investigator blind to both EZ lateralization and localization replayed and observed each seizure, noted presence or absence of HP for both hands, and timed the latency of each HP from the beginning of the electrographic seizure, working frame by frame on the video-EEG. Although we initially evaluated HPs of both hands to have a broader view of the phenomenon under investigation, only those HPs arising in the hand contralateral to the EZ were further characterized and analyzed. Our goal for this study was to identify potential EZ localizing signs. As there are no direct connections between the 2 hemispheres for hand motor control, ipsilateral hand movements do not directly reflect activity in the hemisphere that contains the EZ, hence our decision to later focus only on contralateral HP. Each seizure containing a contralateral HP was replayed a second time, and 2 investigators (now blind to EZ localization

but not lateralization) took individual screenshots of each HP. This was done to facilitate comparison of all ictal HPs and their classification in a clinically useful chart. For consistency, screenshots were taken at 5 seconds after the beginning of the HP. The same 2 investigators working together classified all HPs as in Figure 2. Finally, 3 independent observers (also blind to EZ localization but not lateralization) observed the screenshots of all contralateral HPs and categorized each patient by HP following the chart in Figure 2. Only at this point was EZ localization paired to each patient (Fig 3).

Statistical procedures are listed under the corresponding results section.

Results

A total of 79 patients satisfied our inclusion criteria. Of these, 6 were excluded because their hands were never clearly visible. Of the remaining patients, 40 were frontal lobe and 33 temporal lobe patients, for a total of 489 seizures. If a patient presented an HP in at least 1 seizure, the patient was considered to be HP+. A total of 54.5% of temporal patients and 72.5% of frontal patients presented ictal HP in at least 1 of their seizures, but this difference did not reach statistical significance (standard error for difference = 0.112, 95% CI = -0.044 to 0.404). A greater percentage of seizures demonstrated HPs for HP+ temporal lobe epilepsy than for HP+ frontal lobe epilepsy ($\chi^2 = 5.220$, 2-tailed $p = 0.0233$ with Yates continuity correction; see Fig 1C). In our study, we did not find any differences in the number of observed seizures per patient based on EZ localization. In particular, for HP+ patients, the average number of analyzed seizures per patient \pm standard error of the mean (SEM) was 5.3 ± 0.9 (frontal

and 5.3 ± 0.6 (temporal), $p = 0.42$. The average number of HP+ seizures per patient \pm SEM was 3.5 ± 0.6 (frontal) and 4.3 ± 0.5 (temporal), $p = 0.42$. The average number of HP- seizures per patient \pm SEM was 1.8 ± 0.5 (frontal) and 1.0 ± 0.3 (temporal), $p = 0.38$, 2-tailed nonparametric Mann–Whitney test.

Not surprisingly, contralateral HPs tend to appear earlier in the seizure and almost twice as often. Average latency \pm SEM from the beginning of the electrographic seizure was 7.99 ± 0.25 seconds for contralateral HPs and 11.92 ± 0.47 seconds for ipsilateral HPs, $p = 0.0474$, 2-tailed unpaired t test with Welch correction for unequal variances. If we further characterized latency by EZ localization, frontal seizures had a shorter contralateral HP latency compared to temporal seizures (6.11 ± 0.34 seconds compared to 10.08 ± 0.38 seconds, $p = 0.009$, 2-tailed unpaired t test). Additionally, contralateral HP was present in 86% of HP+ seizures, in contrast to ipsilateral HP, which manifested in only 48% of HP+ seizures.

Most HP+ patients presented contralateral only or bilateral HPs (23 frontal, in 15 males and 8 females; 17 temporal, in 8 males and 9 females). Seven patients (6 frontal and 1 temporal) were not further characterized because they presented only ipsilateral HPs. The distribution of ipsilateral, bilateral, or contralateral HPs was not different between frontal and temporal patients ($\chi^2 = 0.01705$, 2-tailed $p = 0.8961$; see Fig 1D, E). We found no correlation between HP type and gender.

We took pictures of each ictal HP to create categorical classes of HPs (see Fig 2A, B). Classification was done based on the reciprocal positions of the fingers. HPs are generated by a combination of flexion or extension of the fingers at metacarpophalangeal and interphalangeal joints (see Fig 2C). We identified the thumb and index finger as independent fingers, whereas fingers 3 to 5 generally had reciprocal similar positioning in the same HP. HPs were labeled depending on the function they evoke: “fist,” “hand cup,” “politician’s fist” (for the resemblance with a classical hand gesture that is popular among politicians, as it is thought to be perceived as a less aggressive form of a clenched fist), “pincer,” “extended hand,” and “pointing” posture.

Each seizure was independently evaluated; therefore, 1 patient may present >1 HP. Of note, only 2 frontal patients presented HPs suggestive of both frontal and temporal EZ localizations (fist and politician’s fist). All other patients that presented >1 HP had either frontal lobe EZ localization with a combination of both fist and pointing HPs, or temporal lobe EZ localizations, with a combination of cup, pincer, and politician’s fist HPs. A summary of the number of patients with specific HPs can be found in Figure 3. Interrater reliability of patients’ categorization




FIGURE 4: Representative hand posture (HP) of a 34-year-old female patient showing ictal left-hand politician’s fist posturing. We report this patient because her HP remained unchanged after a right parietal lesionectomy that did not lead to seizure freedom, which was accomplished 2 years later after right anteromedial temporal resection. [Color figure can be viewed at www.annalsofneurology.org]

by HP was 95.96% with a calculated Fleiss fixed-marginal multirater kappa of 0.95 (95% CI = 0.86–1.00).

Patients were grouped by EZ localization. Exact contingency table analysis revealed a significant relationship between HP and EZ localization ($p < 0.00001$). For each HP, we calculated sensitivity, specificity, PPV, and NPV, and accuracy for the EZ localization they associated with, against other types of HP, but not their absence. For instance, for a particular HP, each value represents sensitivity, specificity, PPV, NPV, and accuracy for temporal or frontal lobe EZ localization only when an HP is present. A summary of these results, with 95% CIs in brackets (where appropriate), can be found in Figure 3.

Case Report

We report a unique occurrence in our patient group as a case report. A 34-year-old female patient had a right parietal lobe lesion removed in 2003, which was thought to be epileptogenic. In the following 2 years, her seizures persisted, unchanged in semiology, severity, and frequency. In 2005, following a second evaluation, the EZ was localized to her right temporal lobe, and the patient underwent right anteromedial temporal resection. Since then the patient has been seizure-free. We analyzed all seizures from the 2003 and 2005 evaluations, and her seizures appeared identical. Interestingly, in videos of both evaluations, her ictal left HP corresponded to what we classified as politician’s fist (Fig 4), which according to our study suggests a temporal lobe EZ localization. For this patient, we analyzed a total of 9 seizures, all of which were HP+. The average latency \pm SEM from the beginning of the electrographic seizure was 9.78 ± 3.53 seconds.

Discussion

In this retrospective study, we identified several HPs that might predict temporal or frontal lobe EZ localization. In particular, cup, politician's fist, and pincer postures predict temporal lobe localization, whereas fist and pointing postures predict frontal lobe localization. A less frequently seen posture (extended hand) may have high specificity but is too rare for a conclusion to be drawn.

This study identifies, for the first time, specific HPs as common localizing signs that may become important complementary tools in the presurgical evaluation of patients with intractable epilepsy, as in the presented case report. Additionally, this study also carries interesting neurophysiological and neurofunctional implications.

Concerning the temporal lobe, a depth electrode study¹⁴ showed how seizures that remain confined within the temporal lobe never present with HPs. Contrary to what happens in frontal lobe seizures, we observed how, in temporal lobe seizures, ictal HPs only appeared with impaired awareness; therefore, they must be generated from propagation of the epileptic discharge to extratemporal or subcortical areas. Given the stereotyped nature of temporal HPs and the lack of overlap between temporal and frontal HPs, it is more likely that temporal HPs arise from activation of subcortical rather than cortical motor regions, as both hippocampus and amygdala are strongly connected with basal ganglia, whereas frontal HPs probably arise following activation of motor or premotor cortices. Some supporting evidence comes from subdural grid recordings and ictal imaging of temporal lobe seizures.^{8,28} Kotagal et al showed how seizures with dystonic posturing may not propagate to suprasylvian areas.⁹ Fifteen years later, Mizobuchi et al reported that ictal upper extremity posturing correlated with putamen hyperperfusion that was not present in temporal lobe seizures without posturing.²⁸

Remarkably, the 3 HPs that predict temporal lobe localization (cup, politician's fist, and pincer) appear identical in the position of thumb, index finger, and middle finger, and they require the engagement of the same muscle groups. The function of these 3 HPs resembles that of fine prehension. We therefore propose these HPs to be similar in nature. They are often present in the same patient, and sometimes it is difficult to unequivocally distinguish them.

Functionally, there may be a preferential neural connection between the temporal lobe and cortical and subcortical regions that evoke grasping postures. Although the neural basis of tool use remains largely elusive, a growing body of evidence points to the temporal lobe as the area where semantic and conceptual information for tools is stored.^{29–33} Tool

recognition, planning of prehension gestures, and hand–tool interactions derive from complex interplay between the ventral and dorsal streams and different areas of occipital, temporal, frontal, and parietal lobes. But the temporal lobe may function as a fundamental hub in the cross talk between these areas, as revealed by tract tracing studies.³¹

Regarding HPs that correlate with frontal seizure onset, fist and pointing postures, they evoke specific hand gestures, or postures that are used as a form of nonverbal communication.

Developmentally, communicative pointing is the earliest form of nonverbal communication,^{34–38} and its emergence is so universal that it is part of the Modified Checklist for Autism in Toddlers, Revised screening for autism spectrum disorder. Pointing gestures are used to confer imperative, declarative, or informative content to human interactions.³⁹ But despite its importance, little is known about the cortical networks involved in the execution of this complex communication tool. The neurological basis of pointing gestures is thought to be distinguished from other HPs, as it requires the presence of a subject, an object, and an audience. Important insights are gained from deficits in pointing gestures in patients with heterotopagnosia, who specifically lack the ability to perform this 3-way communication task.^{40–42} Interestingly, in the context of our study, a recent positron emission tomographic scan study showed how communicative pointing activated small areas in the medial prefrontal cortex and the temporoparietal junction.⁴⁰ Moreover, the left inferior frontal gyrus has been implicated in the expression of verbal pointing at the agent of an action.⁴³ Ictal pointing posturing may derive from propagation of the epileptic discharge to these cortical areas.

Lastly, clenched fist posture is universally utilized as a confrontational, aggressive gesture. Aggression is a complex social behavior and the emergent property of a brain-wide network. Literature on its neural basis is vast.^{44–50} Both cortical and limbic structures participate in the generation of aggressive behaviors. In particular, prefrontal and orbitofrontal cortices seem to act as inhibitors over lower centers, mostly hypothalamus and amygdala, which on the other hand act as positive modulators of aggressive behaviors. In our study, we did not screen for ictal aggressive behavior; therefore, we cannot determine whether fist HPs were an isolated finding or if they occurred with other displays of aggression. Nonetheless, the appearance of this specific HP only in seizures starting in the frontal lobe has interesting neurobehavioral implications, as the propagating ictal discharge may temporarily cause loss of the inhibitory control of the frontal cortex over subcortical areas and release only partial manifestations of aggression, for example, an aggressive HP.

Future investigation should include a long-term prospective study of ictal HPs to determine whether localization prediction based on ictal HPs will significantly correlate with the localization of surgical resection and later outcome. This will allow validation of our findings and evaluation of the impact of our research on the surgical decision. Additionally, it is entirely possible that seizures starting from lobes other than frontal and temporal may have HPs similar to the ones described here, or different ones. We decided not to pursue this line of research, as in our surgical population the numbers of patients with occipital, parietal, or mixed resections were very limited. Consequently, the incidence of false-positive HPs due to extratemporal or extrafrontal EZs cannot be determined from this study. A similar study of patients who underwent surgery for all focal seizures should be attempted in the future, by possibly combining data from multiple centers. Conclusions reached by this study, therefore, should only serve as a guide for differential localization between temporal and frontal lobe EZs and do not apply to the EZ localization of other lobes, nor to sublobar localizations. Lastly, although contralateral HPs usually appeared before ipsilateral HPs, this information alone is not sufficient to use ictal HPs for lateralization purposes in a clinical setting. Future studies should address differences between contralateral and ipsilateral ictal HPs.

Of note, although we did not analyze the evolution of the primary HP, we noticed that in many cases the initial HP evolved into a different one as the seizure progressed. In particular, many HPs described in this study evolved, later in the seizure, into the classic dystonic HP described by Kotagal et al,⁹ defined as a “forced, unnatural posturing, usually with a rotatory component, easily distinguished from tonic posturing.” In support of this observation, it is interesting to note how latencies of the HPs we describe are 5 to 10 seconds shorter than those reported by Kotagal et al.⁹ It will be interesting in a future study to focus on the secondary evolution of HPs, and to investigate how dystonic posturing correlates with the presence or absence of a preceding specific HP. Evolution may carry significance for localization in relation to the primary HP.

Acknowledgment

This research was funded by a scholarship to I.F. from the Medical School of the University of Bologna, by the scholarship Collegio Superiore of the University of Bologna to I.F., and by NIH grants RO1NS033310 and U54NS100064 to J.E.

We thank Dr G. Ambrosetto, C. Giardini and the Bellaria Neurology team, Dr J. Stern, Dr D. Eliashiv, Dr I. Fried, S. Dewar, K. Shattuck, and B. Salaz.

We confirm that we have read the Journal's position on issues involved in ethical publication and affirm that this report is consistent with those guidelines.

Author Contributions

I.F., J.R.S., C.A.T., and J.E. contributed to the conception and design of the study; I.F., J.R.S., L.T., G.L.R., C.E., and V.S. contributed to the acquisition and analysis of data; I.F., C.A.T., and J.E. contributed to drafting the text and preparing the figures.

Potential Conflicts of Interest

Nothing to report.

References

1. Semah F, Picot MC, Adam C, et al. Is the underlying cause of epilepsy a major prognostic factor for recurrence? *Neurology* 1998;51:1256–1262.
2. Fisher RS, Cross H, French JA, et al. Operational classification of seizure types by the International League Against Epilepsy: Position Paper of the ILAE Commission for Classification and Terminology. *Epilepsia* 2017;58:522–530.
3. Engel J Jr. Etiology as a risk factor for medically refractory epilepsy: a case for early surgical intervention. *Neurology* 1998;51:1243–1244.
4. Hauser WA, Kurland LT. The epidemiology of epilepsy in Rochester, Minnesota, 1935 through 1967. *Epilepsia* 1975;16:1–66.
5. Lüders HO, Engel J Jr, Munari C. General principles. In: Engel J Jr, ed. *Surgical treatment of the epilepsies*. 2nd ed. New York, NY: Raven Press, 1993:137–153.
6. So EL. Value and limitations of seizure semiology in localizing seizure onset. *J Clin Neurophysiol* 2006;23:353–357.
7. Manford M, Fish DR, Shorvon SD. An analysis of clinical seizure patterns and their localizing value in frontal and temporal lobe epilepsies. *Brain* 2007;119(pt 1):17–40.
8. Tassinari CA, Cantalupo G, Högl B, et al. Neuroethological approach to frontolimbic epileptic seizures and parasomnias: the same central pattern generators for the same behaviours. *Rev Neurol* 2009;165:762–768.
9. Kotagal P, Lüders H, Morris HH, et al. Dystonic posturing in complex partial seizures of temporal lobe onset: a new lateralizing sign. *Neurology* 1989;39:196–201.
10. Loddenkemper T, Kotagal P. Lateralizing signs during seizures in focal epilepsy. *Epilepsy Behav* 2005;7:1–17.
11. Janszky J, Fogarasi A, Jokeit H, et al. Lateralizing value of unilateral motor and somatosensory manifestations in frontal lobe seizures. *Epilepsy Res* 2000;43:125–133.
12. Rásonyi G, Fogarasi A, Kelemen A, et al. Lateralizing value of postictal automatism in temporal lobe epilepsy. *Epilepsy Res* 2006;70:239–243.
13. Hirsch LJ, Lain AH, Walczak TS. Postictal nosewiping lateralizes and localizes to the ipsilateral temporal lobe. *Epilepsia* 1998;39:991–997.
14. Leutmezer F, Baumgartner C. Postictal signs of lateralizing and localizing significance. *Epileptic Disord* 2002;4:43–48.

15. Kramer U, Riviello JJ, Carmant L et al. Clinical characteristics of complex partial seizures: a temporal versus a frontal lobe onset. *Seizure* 1997;6:57–61.
16. Ataoğlu EE, Yıldırım İ, Bilir E. An evaluation of lateralizing signs in patients with temporal lobe epilepsy. *Epilepsy Behav* 2015;47:115–119.
17. Kellinghaus C, Loddenkemper T, Kotagal P. Ictal spitting: clinical and electroencephalographic features. *Epilepsia* 2003;44:1064–1069.
18. Raghavendra S, Mirsattari S, McLachlan RS. Ictal whistling: a rare automatism during temporal lobe seizures. *Epileptic Disord* 2010;12:133–135.
19. Loddenkemper T, Kellinghaus C, Gandjouret J, et al. Localising and lateralising value of ictal piloerection. *J Neurol Neurosurg Psychiatr* 2004;75:879–883.
20. Kurita T, Sakurai K, Takeda Y, et al. Pilomotor seizures in temporal lobe epilepsy: a case report with sequential changes in magnetic resonance imaging. *Epilepsy Behav Case Rep* 2013;1:142–145.
21. Swartz BE. Electrophysiology of bimanual-bipedal automatism. *Epilepsia* 1994;35:264–274.
22. Gardella E, Rubboli G, Tassinari CA. Video-EEG analysis of ictal repetitive grasping in 'frontal-hyperkinetic' seizures. *Epileptic Disord* 2006;8:267–273.
23. Souirti Z, Landré E, Mellerio CZ, et al. Neural network underlying ictal pouting ('chapeau de gendarme') in frontal lobe epilepsy. *Epilepsy Behav* 2014;37:249–257.
24. Lüders HO, Najm I, Nair D, et al. The epileptogenic zone: general principles. *Epileptic Disord* 2006;8(suppl 2):S1–S9.
25. Siegel J, Tatum WO. Hand postures in primary and secondary generalized tonic-clonic seizures. *Neurology* 2016;87:1802–1805.
26. Siegel J, Tatum WO. Index-finger pointing in generalized tonic-clonic seizures. *Epilepsy Behav* 2016;58:18–21.
27. Friedman DE, Yoshor D. Early ictal face wiping in frontal lobe epilepsy. *Epilepsy Behav* 2011;20:569–571.
28. Mizobuchi M, Matsuda K, Inoue Y, et al. Dystonic posturing associated with putaminal hyperperfusion depicted on subtraction SPECT. *Epilepsia* 2004;45:948–953.
29. Ramayya AG, Glasser MF, Rilling JK. A DTI investigation of neural substrates supporting tool use. *Cereb Cortex* 2010;20:507–516.
30. Noppeney U. The neural systems of tool and action semantics: a perspective from functional imaging. *J Physiol Paris* 2008;102:40–49.
31. Grafton ST. The cognitive neuroscience of prehension: recent developments. *Exp Brain Res* 2010;204:475–491.
32. Orban GA, Caruana F. The neural basis of human tool use. *Front Psychol* 2014;5:310.
33. Karnath HO, Rüter J, Mandler A, et al. The anatomy of object recognition—visual form agnosia caused by medial occipitotemporal stroke. *J Neurosci* 2009;29:5854–5862.
34. Butterworth G, Morisette P. Onset of pointing and the acquisition of language in infancy. *J Reprod Infant Psychol* 1996;14:219–231.
35. Camaioni L, Perucchini P, Bellagamba F, et al. The role of declarative pointing in developing a theory of mind. *Infancy* 2004;5:291–308.
36. von Hofsten C, Dahlström E, Fredriksson Y. 12-month-old infants' perception of attention direction in static video images. *Infancy* 2005;8:217–231.
37. Esteve-Gibert N, Prieto P. Infants temporally coordinate gesture-speech combinations before they produce their first words. *Speech Commun* 2014;57:301–316.
38. Bakker M, Kaduk K, Elsner C, et al. The neural basis of non-verbal communication-enhanced processing of perceived give-me gestures in 9-month-old girls. *Front Psychol* 2015;6:59.
39. Cochet H, Vauclair J. Deictic gestures and symbolic gestures produced by adults in an experimental context: hand shapes and hand preferences. *Laterality* 2014;19:278–301.
40. Cleret de Langavant L, Remy P, Trinkler I, et al. Behavioral and neural correlates of communication via pointing. *PLoS One* 2011;6:e17719.
41. Felician O, Ceccaldi M, Didic M, et al. Pointing to body parts: a double dissociation study. *Neuropsychologia* 2003;41:1307–1316.
42. Degos JD, Bachoud-levi AC, Ergis AM, et al. Selective inability to point to extrapersonal targets after left posterior parietal lesions: an objectivization disorder? *Neurocase* 1997;3:31–39.
43. Løevenbruck H, Baciú M, Segebarth C, et al. The left inferior frontal gyrus under focus: an fMRI study of the production of deixis via syntactic extraction and prosodic focus. *J Neurolinguistics* 2005;18:237–258.
44. Bartholow BD. The aggressive brain: insights from neuroscience. *Curr Opin Psychol* 2018;19:60–64.
45. Repple J, Pawliczek CM, Voss B, et al. From provocation to aggression: the neural network. *BMC Neurosci* 2017;18:73.
46. Achterberg M, van Duijvenvoorde ACK, Bakermans-Kranenburg MJ, et al. Control your anger! The neural basis of aggression regulation in response to negative social feedback. *Soc Cogn Affect Neurosci* 2016;11:712–720.
47. Siegel A, Victoroff J. Understanding human aggression: new insights from neuroscience. *Int J Law Psychiatry* 2009;32:209–215.
48. Blair RJR. The roles of orbital frontal cortex in the modulation of antisocial behavior. *Brain Cogn* 2004;55:198–208.
49. Nelson RJ, Chiavegatto S. Molecular basis of aggression. *Trends Neurosci* 2001;24:713–719.
50. Damasio H, Grabowski T, Frankel R, et al. The return of Phineas Gage: clues about the brain from the skull of a famous patient. *Science* 1994;264:1102–1105.